

Bilateral Tubo-Ovarian Abscess after Cesarean Delivery: A Case Report and Literature Review

Sorayya Saleh Gargari¹, Samaneh Esmaeili¹, Maasoumeh Saleh¹, Fereshteh Bagherifard²

¹Department of Gynecology and Obstetrics, ²Department of Anaesthesiology, Mahdyyeh Hospital, ShahidBeheshti University of Medical Sciences, Tehran, Iran

Corresponding Author: Maasoumeh Saleh

ABSTRACT

Tubo-ovarian abscess (TOA) is extremely rare condition during the pregnancy and the postpartum period because the cervical mucus plug and intact amniotic membrane protect against ascending infection. It is mostly associated with endometrioma, assisted reproduction techniques and cesarean delivery. We herein report a 32-year-old woman with bilateral endometrioma who underwent emergency cesarean delivery due to placenta previa and was diagnosed to have TOA about 2 months after the delivery. She was managed medically by intravenous antibiotics without response and thus underwent surgical drainage and cyst removal. She had an uneventful postoperative period and was symptom-free at 6-month follow-up. In postpartum period, early diagnosis of pelvic inflammatory disease (PID) and TOA is crucial to prevent complications. Also, TOA symptoms are non-specific, so clinical suspicion and then evaluation with imaging is necessary to prevent fatal complications including abscess rupture, peritonitis and sepsis.

Key words: Ovarian Abscess; Cesarean Delivery; Endometrioma; Puerperium

INTRODUCTION

Tubo-ovarian abscess (TOA) is extremely rare condition during the pregnancy and the postpartum period because the cervical mucus plug and intact amniotic membrane protect against ascending infection. (1-3) The condition is associated with increased maternal mortality and morbidity as well as increased complication of the newborn. (4) Several

conditions are associated with increased risk of TOA during the pregnancy including assisted reproduction techniques (ART), (5) endometriosis and endometrioma (5,6) and cesarean sections. (3) Several pathomechanisms are proposed for TOA during the pregnancy including the hematogenous spreading, lymphatic spreading from contiguous organ, infection in a previously existing ovarian cyst, and flare-up of an old infection. (7,8) Appropriate management is crucial, because there are potentially severe short-term consequences (such as abscess rupture and ensuing peritonitis and sepsis) and long-term consequences (such as infertility, ectopic pregnancy, and chronic abdominal/pelvic pain). (9) In general, TOA responds well to the empirical antibiotic regimen recommended by Center for Disease Control and Prevention. However, approximately 25% of TAO cases need surgical intervention or drainage. (10) We herein report a rare case of TOA in postpartum period of a patient undergoing cesarean section.

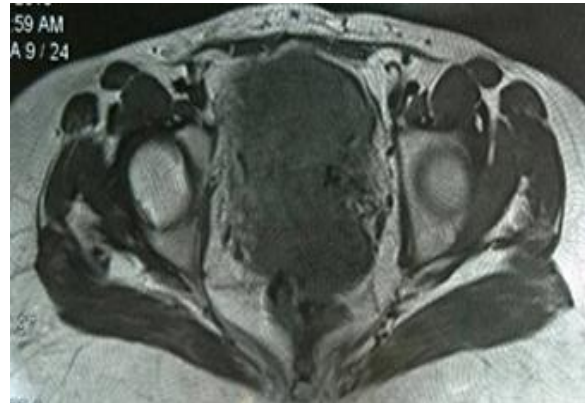
CASE REPORT

A 32-year-old Iranian woman (gravid 1, para 1, living 1) was admitted to our center with abdominal pain. She complained of fever and lower abdominal pain, since 2 months ago, (beginning 1 month after her cesarean delivery). She was married for 10 years and suffered from primary infertility for 6 years. She has been diagnosed with bilateral endometriomas and was considered to have frozen pelvis. Her pregnancy was a result of a successful intra-

cytoplasmic sperm injection (ICSI). She denied any history of intravenous drug abuse, smoking, alcohol intake, or abdominal trauma. There was no history of symptomatic pelvic inflammatory disease. Her partner was healthy and denied any history of sexually transmitted infections (STD). Her pregnancy was terminated 3 months prior to this admission due to severe vaginal bleeding; when she underwent emergency caesarean section for placenta previa, at 28 weeks of gestation. Her postpartum period was uneventful and she was discharged after 2 days in good condition. She experienced persistent chills, fever and lower abdominal pain that began in the fourth post-partum week and deteriorated over time. Her abdominal pain was prominent in right lower quadrant. She received several antibiotics without improvement. On admission, she was ill, pale and febrile (oral temperature was 38°C). Her blood pressure, heart rate and respiratory rate was 110/70 mmHg, 98 beats/min and 18 per minutes, respectively. There was no guarding or rigidity except mild tenderness of right lower quadrant on abdominal examination. On pelvic examination, the speculum examination was normal, no vaginal discharge was seen. A markedly tender mass, was palpable in the right adnexal area. Laboratory studies, showed anemia with hemoglobin level of 8.7 g/dl and neutrophilic leukocytosis (a white blood cell count of 16000/mm³, 80% were polymorphonuclear neutrophilia). Cross-Reacting Protein level (CRP), Estimated Sedimentation Rate (ESR) and CA-125 level were elevated. Her blood culture was negative. Abdominopelvic ultrasonography 1 month prior to admission revealed a cystic lesion 37×41 mm in right ovary and multiple follicles in left ovary. In our center, ultrasonographic examination revealed a cyst measuring 45×50 mm in right ovary and another cyst measuring 33×35 mm in left ovary. Magnetic Resonance Imaging (MRI) revealed a right multi-loculated cyst measuring 87×102 mm and a left cyst of about 40 mm in diameter

(Fig. 1). A pelvic computed tomography (CT) scan revealed a right adnexal mass originating from the tube and ovary compatible with a pelvic abscess.

Fig.1: Axial T2-weighted magnetic resonance imaging (MRI) of the patient revealing right multi-loculated cyst measuring



87×102 mm and a left cyst of about 40 mm in diameter in favor of tubo-ovarian abscess.

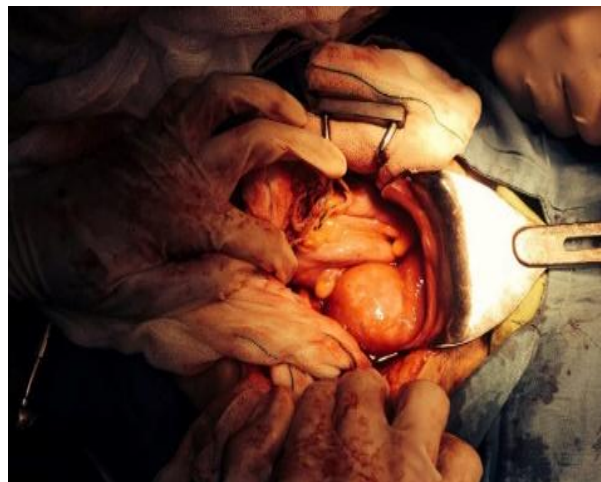

Fig.2. Intraoperative image demonstrating bilateral tubo-ovarian abscess superimposed on bilateral endometrioma. Both abscesses were successfully drained and removed.

Intravenous antibiotic (clindamycin 900 mg TDS and gentamicin 80 mg TDS) was started for 3 days without improvement thus the regimen was changed (imipenem 500 mg QID and vancomycin 1gr BID). Due to clinical deterioration, an exploratory laparotomy was performed revealing severe adhesion bands inside the abdomen. The ovaries were also adherent to the uterus. The adhesion between loops of intestine, ovaries and uterus were all released. There was a 6-cm multi-loculated abscess in the right adnexa; adherent to the uterus, colon and appendix (Fig. 2). The abscess was

completely drained. At left side, a 3-cm abscess was also drained. The abscess wall was also removed. After peritoneal lavage, the abdomen was closed in layers. She was discharged 10 days after the operation, symptom-free, with oral antibiotics. She had an uneventful postoperative period and was well without recurrence at 6-month follow-up.

DISCUSSION

Pelvic inflammatory disease (PID) is a complex poly-microbial disease that is due to the ascending spread of pathogens from the cervix or vagina, most commonly *Chlamydia trachomatis* or *Neisseria gonorrhoeae* (60-75%), which then spread into the endometrium, fallopian tubes, ovaries, and adjacent structures. ⁽¹¹⁾ TOA is a collection of pus involving the ovary and fallopian tube (distal part). TOA most often arises as a consequence of PID. However, TOA can also develop following pelvic surgery, or as a complication of an intra-abdominal process, such as appendicitis or diverticulitis. ⁽¹²⁾ Patients typically present with fever, elevated white blood cell count, lower abdominal-pelvic pain, and/or vaginal discharge. TOA are often poly-microbial with a high percentage of anaerobic bacteria.

TOA is relatively rare in pregnancy and postpartum period. Infection of the ovary readily occurs in the puerperium if there is infection of the birth canal during or following parturition. ⁽¹³⁾ Chayachina et al. ⁽²⁾ reported a case of TOA caused by *Fusobacterium necrophorum* three weeks after vaginal delivery with a tubal sterilization on the following day. TOA involvement of an endometrioma has been reported in cases of patients with poly-microbial sources but Kavoussi et al, ⁽¹⁴⁾ reported a case of endometrioma complicated by TOA in woman with bacterial vaginosis (BV). They concluded, aggressive treatment of bacterial vaginosis in patients with known advanced-stage endometriosis may be considered to prevent super infected endometriomas. ⁽¹⁴⁾ The

development of TOA among women with endometriomas may be due to increased susceptibility to infection, particularly in the altered immune environment seen with ectopic endometrial glands and stroma, although there are no epidemiologic data available to support this theory. ^(6,14) Previous surgical procedures involving the pelvic organs have been found to increase the risk of TOA formation in patients with endometriosis. ⁽⁸⁾ The majority of endometriomas decrease in size during pregnancy particularly high in desidualised endometriomas. ⁽⁵⁾ High progesterone levels produced during pregnancy and temporary cessation of menstrual cycles and induced apoptosis are probably the main factors causing regression of endometriosis. ⁽⁵⁾ In our case, the patient had growth of endometriomas after pregnancy termination due to decreased level of progesterone and it seems that bilateral endometriomas superinfected by microorganisms due to incomplete treatment of PID.

Unruptured abscess may be treated by the supportive care and treated by preoperative broad-spectrum intravenous antibiotics effective against gram positive, gram negative and anaerobic bacteria for at least 72 hours before operative intervention. Ruptured tubo-ovarian abscess requires an aggressive and primarily surgical approach in order to minimize catastrophic sequelae. Four principle indications for laparotomy, laparoscopy among these patients are: 1- suspicion of a surgical emergency (Rupture of the abscess or organs), 2-unsuccessful drainage of the abscess, 3-poor response to treatment with drainage and antibiotics (like our case), and 4-uncertainly about the diagnosis. ⁽⁸⁾

In conclusion, endometriosis is a risk factor for PID and TOA. In postpartum period, early diagnosis of PID is crucial to prevent complications. Also, TOA symptoms are non-specific, so clinical suspicion and then evaluation with imaging is necessary to prevent fatal complications including abscess rupture, peritonitis and sepsis.

Conflict of Interest: The authors have no conflicts of interest relevant to this article

ACKNOWLEDGMENT

We would like to thank the patient and her family who participated in this study. We would also like to acknowledge the editorial assistance of DibaNegar Research Institute for improving the style and English of the manuscript.

REFERENCES

1. Abdou R, Miller T. Postpartum tubo-ovarian abscess, likely arising from pelvic inflammatory disease during pregnancy. *BMJ Case Rep.* 2017;2017.
2. Chayachinda C, Leelaporn A, Ruangvutilert P, Thamkhantho M. Post-partum, post-sterilization tubo-ovarian abscess caused by *Fusobacterium necrophorum*: a case report. *J Med Case Rep.* 2012;6:330.
3. Erdem M, Arslan M, Yazici G, Erdem A, Gursoy R. Incidental tubo-ovarian abscess at abdominal delivery: a case report. *J Matern Fetal Neonatal Med.* 2002;12(4):279-80.
4. Eperon I, Liberek C, Irion O, Martinez De Tejada B. Neonatal pneumococcal sepsis associated with maternal tubo-ovarian abscess. *J Obstet Gynaecol.* 2013;33(4):416-7.
5. Villette C, Bourret A, Santulli P, Gayet V, Chapron C, de Ziegler D. Risks of tubo-ovarian abscess in cases of endometrioma and assisted reproductive technologies are both under- and overreported. *Fertil Steril.* 2016;106(2):410-5.
6. Kitamura S, Matsumura N, Ohtake N, Kita M, Konishi I. Tubo-ovarian abscess with endometrial cyst probably infected by *Campylobacter fetus*: Two cases. *J Obstet Gynaecol Res.* 2016;42(8):1052-7.
7. Han C, Wang C, Liu XJ, Geng N, Wang YM, Fan AP, et al. In vitro fertilization complicated by rupture of tubo-ovarian abscess during pregnancy. *Taiwan J Obstet Gynecol.* 2015;54(5):612-6.
8. Pabuccu EG, Taskin S, Atabekoglu C, Sonmezer M. Early pregnancy loss following laparoscopic management of ovarian abscess secondary to oocyte retrieval. *Int J Fertil Steril.* 2014;8(3):341-6.
9. To V, Gurberg J, Krishnamurthy S. Tubo-Ovarian Abscess Caused by *Candida Albicans* in an Obese Patient. *J Obstet Gynaecol Can.* 2015;37(5):426-9.
10. Granberg S, Gjelland K, Ekerhovd E. The management of pelvic abscess. *Best Pract Res Clin Obstet Gynaecol.* 2009;23(5):667-78.
11. Bugg CW, Taira T. Pelvic Inflammatory Disease: Diagnosis And Treatment In The Emergency Department. *Emerg Med Pract.* 2016;18(12):1-24.
12. Chia CC, Huang SC. Ruptured tubo-ovarian abscess in a postmenopausal woman presenting with septic shock: a case report and literature review. *Taiwan J Obstet Gynecol.* 2006;45(1):89-91.
13. Laohaburanakit P, Treevijitsilp P, Tantawichian T, Bunyavejchevin S. Ruptured tuboovarian abscess in late pregnancy. A case report. *J Reprod Med.* 1999;44(6):551-5.
14. Kavoussi SK, Pearlman MD, Burke WM, Lebovic DI. Endometrioma complicated by tubo-ovarian abscess in a woman with bacterial vaginosis. *Infect Dis Obstet Gynecol.* 2006;2006:84140.

How to cite this article: Gargari SS, Esmaeili S, Saleh M et al. Bilateral tubo-ovarian abscess after cesarean delivery; a case report and literature review. *Galore International Journal of Health Sciences & Research.* 2017; 2(3): 30-33.
